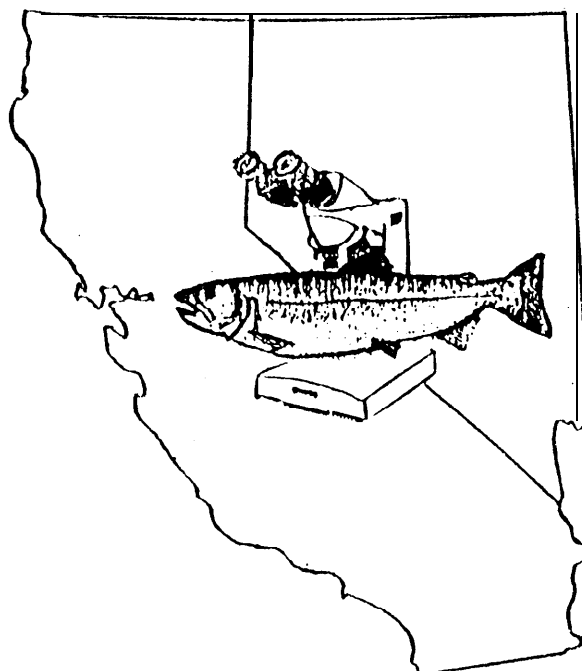


**DISEASE SURVEY OF TRINITY RIVER
SALMONID SMOLT POPULATIONS
1991 REPORT**



**U. S. Fish & Wildlife Service
California - Nevada Fish Health Center
Anderson, California**



**DISEASE SURVEY OF TRINITY RIVER SALMONID
SMOLT POPULATIONS**

1991

J. Scott Foott

Robert L. Walker

U. S. Fish & Wildlife Service

California-Nevada Fish Health Center

Route 1, Box 2105

Anderson, CA 96007

Funded in part by:

Trinity River Basin Fish and Wildlife Management Program

ABSTRACT

Juvenile chinook (*Oncorhynchus tshawytscha*), steelhead (*O. mykiss*), and coho (*O. kisutch*) of hatchery and natural origin were examined for health condition and selected pathogens at several points during their emigration down the Trinity river. Health condition was ascertained by organosomatic analysis of sub-samples from each study group. Infections of *Renibacterium salmoninarum*, *Nanophyetus salmincola* metacercaria, and glochidia were common pathogens encountered in most study groups. The Trinity river hatchery (TRH) coho were judged to be in poor health primarily due to severe bacterial kidney disease. In pre-release samples, Infectious Hematopoietic Necrosis Virus (IHNV) was detected in TRH chinook and Erythrocytic Inclusion Body Syndrome (EIBS) viral inclusions were observed in TRH coho. Neither of these viral diseases were later detected in emigrants sampled down-river. Emigrant fish demonstrated physical signs consistent with smoltification and the rigors of migration. Disease may be influencing smolt survival in several Trinity river stocks.

TABLE OF CONTENTS

ACKNOWLEDGEMENTS

INTRODUCTION

METHODS

SITES

STUDY PERIOD AND GROUPS

FIELD PROTOCOLS

ORGANOSOMATIC ASSAYS

MICROBIOLOGICAL ASSAYS

RESULTS AND DISCUSSION

CHINOOK

STEELHEAD

COHO

DISCUSSION AND SUMMARY

REFERENCES

APPENDICES (only first appendix of two included in this database)

ACKNOWLEDGEMENTS

This survey was funded in part by the Trinity River Basin Fish and Wildlife Management Program (P.L. 98-541). We thank Chuck Lane and Joe Krakker of the Trinity River Fisheries Resource Office, Weaverville, CA for their help and support of this study. We thank Mel Willis (CDFG) for his help in sampling at Trinity river hatchery and the loan of histology equipment. Trinity river hatchery staff are thanked for their aid in sampling at the hatchery. The Coastal California Fisheries Resource Office, USFWS, Arcata was responsible for emigrate capture at both the Willow creek trap and various sites in the Klamath river estuary. In particular, we thank Jim Craig and Greg Goldsmith for their help.

INTRODUCTION

Salmon and steelhead runs have undergone serious declines in the Klamath basin due to a variety of factors including water diversion, sedimentation of stream beds and harvest (Calif. Advisory Comm. on Salmon and Steelhead, 1988). Mitigation hatchery programs in the basin currently release millions of juvenile salmonids (smolts) into the Trinity and Klamath river in an effort to preserve these stocks. Disease can play a major role in smolt migration success. The Trinity and Klamath river systems contain a host of endemic fish pathogens including infectious hematopoietic necrosis virus (IHNV), *Renibacterium salmoninarum* (BKD agent), and *Ceratomyxa shasta* (Hedrick et al. 1987, Manzer 1991, Hendrickson et al 1989). In 1990, erythrocyte inclusions were observed in bloodsmears from anemic coho (*Oncorhynchus kisutch*) and chinook (*O. tshawytscha*) salmon at Trinity River Hatchery (Mel Willis, CDFG, Redding, CA pers. comm.). These clinical signs are suggestive of an infection by the virus responsible for Erythrocytic Inclusion Body Syndrome or EIBS (Leek 1987). Knowledge of the pathogens affecting Trinity River smolts and their incidence rate will provide insight into the general health of emigrants and any role disease may be playing in stock declines.

This report describes the results of a 1991 disease survey performed on natural chinook salmon and steelhead (*O. mykiss*) emigrants, and hatchery coho, chinook, and steelhead juveniles. Hatchery fish were examined at Trinity River Hatchery prior to release. Hatchery and natural emigrants were collected with a rotary trap in the lower Trinity river. In addition to pathogen diagnosis, organosomatic analysis was performed on sub-samples of each group to monitor general health. Significant pathogens detected in the survey included IHNV, EIBS virus-like inclusions, *Renibacterium salmoninarum*, *Nanophyetus salmincola* metacercaria, and glochidia (larval mollusks).

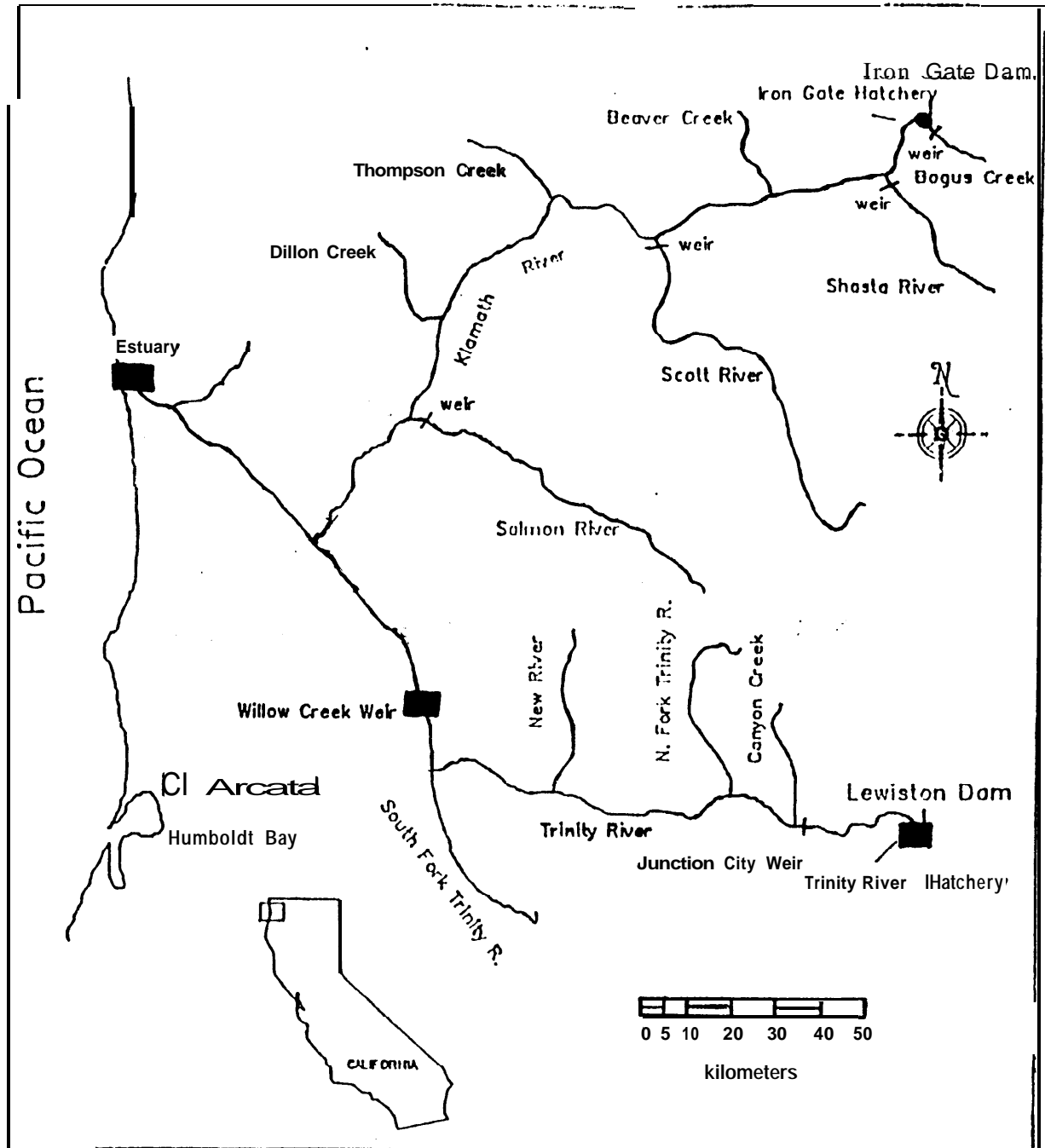


Figure 1. Sampling sites (black boxes) at Trinity River Hatchery, Willow Creek Trap (weir), and Klamath River estuary (modified from map prepared by Coastal California Fishery Resource Office).

METHODS AND MATERIALS

SITES

Trinity River State Fish Hatchery (TRH) salmonids were examined 1 -2 wk prior to their release. The hatchery is operated by the California Department of Fish and Game on mitigation funds administered by the Bureau of Reclamation. The hatchery is located at the base of Lewiston dam (Fig. 1) and rears steelhead trout (*Oncorhynchus mykiss*), coho salmon (*O. kisutch*), and both fall and spring-run chinook salmon (*O. tshawytscha*). These fish are the progeny of Trinity river adults captured and spawned at TRH.

A rotary screw trap (WCT) located at river km 34 near the town of Willow creek was used to capture both hatchery and natural emigrant salmonids (Fig. 1). Natural fish were defined as the progeny of river or tributary spawning adults which had reared as juveniles in these environments regardless of parental genetics (Bjornn 1977). This type of trap tends to capture actively migrating fish in contrast to seining which can also collect resident populations. The rotary screw trap (2.44 m dia.) was fished to a depth of 1.22 m, sampling 2.34 m² of the thalweg (Craig, 1991). Klamath river (upper) estuary samples were collected at six sites between Weitchpec and the US Highway 101 bridge during beach seining operations by the CC-FRO. Chinook juveniles collected in June and July with adipose fin clips were sacrificed for their coded wire tag. Fish with TRH codes were frozen and shipped to CA-NV FHC for pathogen testing.

STUDY PERIOD & GROUPS

Coho salmon yearlings were examined on March 11, 1991 at TRH 7 d prior to their volitional release from the hatchery. In a volitional release, raceway tail screens are removed to allow the fish access to the river, however, no effort is made to push them out of the raceway for several weeks. The first WCT sample of emigrant TRH coho occurred on May 14 (57 d post-release) and a second sample was taken on May 22 (65 d post-release). The first TRH coho capture (12 fish) at WCT occurred the week prior to the May 14 sample. Only 26 natural coho were captured at WCT from February to November 1992. The inability to obtain more than 20 natural coho in a 3 d period precluded any sampling from this group.

Steelhead yearlings were examined on March 11, 1991 at TRH 7 d prior to their volitional release. Emigrant TRH steelhead were sampled at WCT on April 22 (33 d post-release), May 6 (49 d post-release), and May 14 (57 d post-release). The April 22 sample was taken 1 week after the initial arrival of this group (10 fish captured) at the WCT. Natural steelhead yearlings were sampled at WCT on March 13, 1991.

Hatchery spring chinook juveniles were examined on May 21, 1991 at TRH 7 d prior to release (non-volitional). Due to low numbers, all Fall-run chinook at TRH were released in the fall of 1991. Emigrant TRH chinook were sampled at WCT on June 13 (16 d post-release) and estuary samples were collected during the period from June - July 1991. The June 13 sample corresponded to the second week of capture as well as the peak capture period at WCT for this group. Natural chinook juveniles were sampled at WCT on May 14 and 24, 1991.

FIELD PROTOCOL:

TRINITY R. HATCHERY (TRH)

A total of 60 fish per species were netted from several regions of 2 raceways and euthanized by

an overdose of MS-222 (Argent Chemical Laboratories, Redmond, Washington). The caudal peduncle was severed for preparation of blood smears. Skin scrapings, excised gill filaments, and lower intestine content smears were examined for parasites by phase microscopy soon after euthanasia. Kidney and spleen tissue was aseptically dissected from each fish with sterile forceps and placed in 1.8 mL Hanks Buffered Salt Solution (HBSS 10X solution 50 mL, TRIS buffer 2 mL, Sterile deionized water 450 mL) . Tissues from two fish were pooled into one sample and held on ice until processed at the laboratory. Imprints of kidney tissue on 75 x 25 mm slides were fixed in methanol. Twenty of the 60 fish sampled were used for organosomatic analysis.

WILLOW CREEK TRAP (WCT)

Smolts captured at the Willow creek trap (WCT) were held within in-situ liveboxes for up to 3 days. If fewer than 20 smolts of given sample group were collected in a 3 d period, the captured fish were released. Hatchery smolts were identified by CC-FRO personnel using the following criteria: Yearling steelhead = left ventral fin clip; Coho salmon = arrival time at trap, fork length (larger than natural) and erosion of fins; and Chinook salmon = adipose clip. Natural steelhead were selected if they were silver and had no fin marks. Natural chinook were collected at WCT prior to the hatchery release of the Spring chinook juveniles.

Field examination procedures of captured smolts were similar to those described above. The organosomatic analysis was performed on the first 20 fish per group captured at the trap. Kidney and gill tissue from smolts exhibiting parasite infections were placed in Davidson's fixative for 24 hrs, processed for paraffin sections, and stained with Harris hematoxylin and eosin stain (Humason 1979).

ORGANOSOMATIC ASSAYS

A necropsy based fish condition assessment system developed by Ron Goede of the Utah Division of Wildlife Resources (Goede and Barton 1987) was modified for the smolt organosomatic assays (Foott 1990). The assay promotes consistent observation and reporting of the gross morphology of selected organs, hematological parameters, and size criteria for each individual in a 20 fish sample (Appendix 1). A numeric "severity" score (0,1,2,3) is assigned to each tissue where zero is normal and 3 represents severe abnormality. All of the fish's tissue scores are summed to obtain an Abnormality score. A low score represents an apparent healthy fish. The mean sample Abnormality score is a relative health indicator of the population and can be used for comparison to other populations. Those tissues which showed abnormality in > 10 % of the fish were reported as "ABNORMAL TISSUES" in the organosomatic tables. A Lotus 1-2-3™ spreadsheet was developed to calculate the various indices. Electrical power to operate the centrifuge, balance, and phase microscope was supplied by an automobile battery through a power inverter (TrippLite, Chicago IL). Parametric data such as weight, length, condition factor (K), hematocrit, and plasma protein concentration were tested for significance by Student's T-test.

MICROBIOLOGICAL ASSAYS:

VIRAL

Kidney and spleen tissue pools were placed in sterile plastic bags, diluted 1 : 10 in HBSS, homogenized with a Stomacher™ tissue homogenizer, and the mixture centrifuged at 1300 x g, 4 C, for 10 min.. The supernatant of two samples (250 µL each) were combined to form a 4 fish pool and added to 500 µL of an antibiotic solution (1000 IU Penicillin G, 1000 IU Streptomycin sulfate, and 2.5 µg Amphotericin B /mL). The remaining tissue pellet was used for the bacterial assays described below.

Pooled supernatants were diluted 1:10 and 1:100 in HBSS (final sample dilution = 1:200 and 1:2000 respectively) and 100 µL of diluted sample inoculated onto pre-formed EPC and CHSE-214 cells in replicate wells of a 96 well plate. After 45 min. incubation, 100 µl of minimum essential media with 4% fetal bovine serum (MEM-4) with the same antibiotic mixture described above was added to each well. The plates were incubated for 18 days at 15 °C and examined every 2-3 days for Cytopathic effect (CPE). Identification of Infectious Hematopoietic Necrosis Virus (IHNV) was by the coverslip culture / indirect fluorescent antibody technique of La Patra et al. (1989).

BACTERIAL

Once the supernatant from the 2-fish kidney-spleen homogenate was removed for the viral assay, a sample of the tissue pellet was inoculated onto Brain Heart Infusion Agar and incubated for 4 days at 20 °C. Bacterial isolates which were motile, oxidase positive, fermentative, gram-negative rods were presumptively identified as *Aeromonas hydrophila*.

Smears were prepared from the tissue pellets, fixed in xylene, and stained with a fluorescent antibody conjugate specific for *Renibacterium salmoninarum* (Kirkegaard- Perry, Labs). A Zeiss fluorescent microscope was used to scan 50 fields of each smear at 1000X magnification. The sample was considered positive for *R. salmoninarum* if cells of morphology identical to the positive controls reacted with the conjugate.

SMEARS AND IMPRINTS

Blood smears and kidney imprints were air dried for 5 min, fixed in absolute methanol, and stained for 60 s in 0.5 % (w/v in 70 % ethanol) pinacyanol chloride (Sigma Chemical Co.- Cat. No. P-0392). Thirty fields at 1000X oil immersion were examined on each slide for viral inclusions or parasites.

RESULTS & DISCUSSION

CHINOOK

Natural Chinook

Natural chinook juveniles were sampled twice at the WCT in May (Table 1). No significant viral, bacterial, or parasitic pathogens were detected in these fish, however, examination of the stained kidney imprints was not judged adequate for detection of macroparasites such as *Nanophyetus salmincola* metacercaria. The detection of metacercaria in kidney tissue requires either examination of histological sections from fixed tissue or squash preparations by phase microscopy. Histological sections of the natural chinook gills were normal in appearance and did not contain any parasites.

The low Abnormality score from the organosomatic analysis and the lack of detectable pathogens indicate that the natural chinook juveniles were in good health (Table 2). Blood characteristics were not measured due to the insufficient blood volumes of these small fish (Avg. length = 75 mm). There was a wide variation in weight and 80 % of the fish sampled had visible mesenteric fat. The mean condition factor (K) of 0.8920×10^{-5} was slightly higher than the average value of 0.8190×10^{-5} given for chinook (Piper et al 1982). The normal condition factor and fat level indicates that these fish were adequate diets and high energy stores.

Hatchery Chinook

Hatchery spring chinook juveniles (6 mo.) at TRH had been experiencing a high, chronic mortality due to IHNV since March. The virus was detected in 20 % of the pre-release samples but not in fish taken at WCT 16 days post-release (Table 3). It is possible that IHNV infected chinook did not migrate as fast as uninfected cohorts or they that died prior to reaching WCT.

Erythrocyte inclusions, indicative of EIBS virus infection, were not detected in samples taken at either pre-release or after 16 days of emigration (Table 3). Coho salmon concurrently held at the hatchery were EIBS positive and chinook are reported to be susceptible to the EIBS virus (Leek 1987). Light infections can be missed due to the low sensitivity of the bloodsmear method.

The incidence of *R. salmoninarum* infection ranged from 3 - 10 % in samples taken at TRH, WCT, and the Klamath R. estuary (Table 3). The actual incidence of *R. salmoninarum* is probably higher, as the DFAT assay used is only moderately sensitive (Sakai et al. 1989). While no clinical signs of Bacterial Kidney Disease (BKD) were observed in these fish, the progressive nature of BKD in saltwater suggests that a sizable portion of the lot will develop the disease and many more will be carriers (Banner et al. 1983). The isolation of *Aeromonas hydrophila* from asymptomatic fish at both TRH and WCT is not unusual as this aquatic bacterium is commonly found in fish tissues.

TABLE 1. Natural Trinity River Chinook Emigrants: Incidence of virus infection in 4-fish kidney pools, Erythrocytic Inclusion Body Syndrome (EIBS) viral inclusions in individual blood smears, Renibacterium salmoninarum in 2-fish kidney pools, and parasites in individual imprints, smears, wet mounts and histological samples. Fish sampled at the Willow creek trap on May 14 and 22, 1991. Reported as number positive over number sampled (% positive).

	MAY 14	MAY 22	INCIDENCE
VIRUS	0/8	0/7	0/15 (0)
EIBS	0/32	0/30	0/62 (0)
BACTERIA			
<i>R. salmoninarum</i>	0/15	0/12	0/27 (0)
PARASITES			
Skin:	0/8	ND	0/8 (0)
Gill:	0/14	ND	0/14 (0)
Intestine:			
Metacercaria*	1/6	ND	1/6 (0)
Blood:	0/3	0/30	0/62 (0)
Kidney (Imprint):	ND	0/9	0/9 (0)

* Unidentified metacercaria.
 ND Not done.

TABLE 2 Natural Trinity River Fall Chinook organosomatic analysis data^{*}. Twenty fish were examined on May 14, 1991 at the Willow Creek Trap. Percentages reflect the number of fish in sample which meet the row criteria.

CUMULATIVE ABNORMALITY SCORE		0.10
FAT LEVEL >0 (%)		80
SILVERED (%)		100

CONDITION FACTOR (k)		
	mean	0.8920
	std	0.2744
	cv	30.76
LENGTH (mm)		
	mean	74.55
	std	12.19
	cv	16.35
WEIGHT (g)		
	mean	4.04
	std	2.60
	cv	64.56

* Hematocrit and plasma protein measurements were not done as fish were not large enough to obtain sufficient blood volumes.

std Standard deviation

cv Coefficient of variation

TABLE 3. Trinity Hatchery Spring Chinook Smolts: Prevalence of infection for Infectious Hematopoietic Necrosis Virus (IHNV) in 4-fish pool kidney-spleen samples and Erythrocytic Inclusion Body Syndrome (EIBS) inclusions in individual blood smears, bacteria in 2-fish pool kidney-spleen samples, and parasites in individual imprints, smears, wet mounts and histological samples. Fish sampled on May 21 at Trinity R. Hatchery (TRH) 7 d prior to release, June 13, 1991 (16 d post-release) at the Willow creek trap (WCT) during emigration, and from Klamath R. estuary (KRE) seine samples done June - July. Estuary samples are from individual fish. Reported as number positive over number sampled (% positive).

	TRH	WCT	KRE
IHNV	3/15 (20)	0/15 (0)	D
EIBS	0/60 (0)	0/40 (0)	ND
BACTERIA			
<i>R. salmoninarum</i>	1/30 (3)	3/30 (10)	2/27 (7)
<i>A. hydrophila</i>	3/30 (10)	3/15 (20)	ND
PARASITES			
Skin:	0/10 (0)	0/10 (0)	ND
Gill:			
<i>Trichophrya</i> spp.	10/16 (63)	0/12 (0)	ND
Glochidia	0/16 (0)	7/12 (58)	ND
Intestine:			
<i>Hexamita</i> spp.	2/4 (50)	0/18 (0)	ND
<i>C. shasta</i> spores	0/4 (0)		0/18 (0)
Blood:	0/60 (0)	0/40 (0)	ND
Kidney (Imprint):	0/20 (0)	0/20 (0)	ND
Kidney (Histology):			
Metacercaria *	0/11 (0)	5/6 (83)	ND

* Metacercaria observed in kidney sections presumed to be *Nanophyetus salmincola*.

ND Not done.

Glochidia (immature mollusk) infection of the gills and metacercaria infection of the kidney were observed in wet mount and histological samples of WCT emigrants. The metacercaria were presumptively identified as *Nanophyetus salmincola* and the glochidia as *Margaritifera margaritifera*, based on parasite morphology, site of infection, geographic location, and host species (Hoffman 1972, Jennings and Hendrickson 1982, Karna and Millermann 1978).

Salmonids are one intermediate host of the digean trematode, *Nanophyetus salmincola*, the final host being a fish-eating mammal. Eggs, shed with the final host's feces, hatch into free-swimming miracidia and infect aquatic snails of the genus *Oxytrema*. Free-swimming cercaria later leave the snail and penetrate the fish's skin. The parasite, now referred to as metacercaria, enters the circulatory system, encysts in various tissues, and will stay with the fish for its entire life.

Nanophyetus salmincola is itself parasitized by the rickettsial organism *Neorickettsia helminthoeca* which causes "salmon poisoning" in canines (Farrell et al. 1964). While metacercaria elicit little inflammation in fish, the parasite cysts cause obstruction and pressure injury to infected tissues (Wood and Yasutake 1956). *Nanophyetus salmincola* metacercaria can be found in variety of tissues and organs, however, this parasite shows a tropism towards the posterior kidney (Millemann and Knapp 1970).

The freshwater mussel, *Margaritifera margaritifera*, releases immobile glochidia into the river current during the early spring. If glochidia encounter the gill region of a fish, it will attach to the host and become encysted. Over the course of 12 weeks to a year (temperature dependent), the glochidia will develop into a juvenile mussel, excyst from the host, and convert to a benthic, free-living form (Young and Williams 1983). Infection by glochidia reduces respiratory efficiency due to blood vessel blockage and hyperplasia of lamellar epithelium. When the developed juvenile mussel excyst, hemorrhaging and secondary infection can occur to the host (Meyers et al. 1980).

It was estimated that a minimum of 10 -15 % of the chinook sampled at WCT had severe infections based on the number of fish with numerous nodules in the gills and kidneys. It appears that the chinook became infected by these parasites during the 16 d period after release from TRH. Histological sections of gill and kidney taken at the hatchery did not contain either of these parasites and clinical signs were not observed during necropsy. The hatchery does not have a history of infection with either parasite (M. Willis, CDFG Redding, CA, pers. comm.). The effect of the acute (within 16 d) challenge by these parasites on smolt health and saltwater adaptation is unclear from the limited data. Histological sections showed only a mild inflammatory response to both parasites, however, sheer numbers may have impaired the metabolic functions of the gill and kidney.

It is doubtful that infections of *Trichophrya* (a filter feeding protozoan which uses the fish as substrate) and *Hexamita* (a flagellate protozoan found in the intestinal lumen) seen in the hatchery fish had much of an effect on their health.

Organosomatic data indicated that the fish sampled at both TRH and WCT were in relatively good health (Table 4). Scale loss was the primary reason for the higher Abnormality score (AS) at WCT compared with the pre-release sample. Scale loss in WCT fish may have occurred during their 3 day live box residence prior to examination and therefore be an artifact. If scale loss is ignored, the AS scores of the hatchery chinook were comparable to the low AS score of the natural chinook (Table 2).

The mean condition factor (K) for the pre-release sample was identical to the reported value for chinook (Piper et al 1982). Although their mean condition factor dropped, fish sampled at WCT were longer and heavier than those sampled at TRH. It is unclear whether the location of the rotary trap was selective for larger chinook and missed smaller fish moving in shallower water. In 1990, two rotary traps were fished side-by-side at WCT and the trap located in shallow water tended to capture smaller chinook (Greg Goldsmith, USFWS, Arcata, CA pers. comm.). Fyke net sampling in the upper Trinity river has shown that salmonids less than 50 mm (total length) tend to

swim in the shallower portion of the river (M. Zuspan, CDFG, Weaverville, CA, pers. comm.). The June 13 WCT sample may have been biased towards large fish.

When compared to the pre-release sample, fish captured at WCT exhibited signs of smoltification (Hoar 1988). These signs included silver appearance, 8 % increase in mean hematocrit, 12 % reduction in mean condition factor, and a 90 % reduction in the number of fish having visible mesenteric fat. While the mean plasma protein concentration from the pre-release sample was greater than that of the WCT sample, both values were within the normal range for chinook (Wedemeyer & Yasutake 1977). The decrease in plasma protein levels seen in WCT fish could be related to reduced feeding or to kidney damage from *Nanophyetus salmincola* metacercaria which impaired the normal reabsorption of plasma protein in the kidney. Differences in weight, length, condition factor, hematocrit and plasma protein between the pre-release and WCT samples were significant at $P < 0.01$.

TABLE 4. Hatchery Spring Chinook Salmon smolt organosomatic analysis data. Twenty fish were examined on May 21 at Trinity River Hatchery (TRH) 7 d prior to their release and 16 d post-release at the Willow Creek Trap (WCT) on June 13, 1991. Percentages reflect the number of fish in sample which meet the row criteria.

	TRH	WCT
CUMULATIVE ABNORMALITY SCORE	0.10	0.40
ABNORMAL TISSUES ⁺		SKIN ⁺⁺
FAT LEVEL >0 (%)	95	5
SILVERED (%)	0	100

CONDITION FACTOR (k)		
mean	0.8190*	0.7206
std	0.0528	0.0631
cv	6.45	8.76
LENGTH (mm)		
mean	88.50	98.30*
std	7.93	10.57
cv	8.96	10.76
WEIGHT (g)		
mean	5.83	6.99*
std	1.65	1.96
cv	28.31	28.08
HEMATOCRIT		
mean	44.05	47.65*
std	3.64	5.53
cv	8.26	11.61
PLASMA PROTEIN		
mean	4.91*	3.79
std	0.37	0.50
cv	7.48	13.11

* Significantly greater (P < 0.01).

+ Tissues listed if > 10 % of sample had abnormal rating in that tissue.

++ Thirty percent of sample had scale loss > 30 % of body surface.

std Standard deviation.

cv Coefficient of variation.

STEELHEAD

Natural Steelhead

Natural steelhead smolts were sampled at WCT 5 days prior to the TRH steelhead release. Both small parr and silvered yearling (1+) smolts were captured by the rotary trap and seining, however, only the smolts were selected for samples. *Renibacterium salmoninarum* was detected in 21 % of the 2-fish pool samples (Table 5). Large numbers of *R. salmoninarum* cells, indicative of active infection, were seen in 2/3 of the positive samples. This finding is unusual as there are few reports of BKD in wild steelhead and no clinical signs were observed in the sampled fish.

Metacercaria (presumptively *Nanophyetus salmincola*) were observed in a wet mount preparation of kidney from one fish having nodules in this organ. The incidence of metacercarial infection could not be determined as histological samples were not taken from these fish. Glochidia were observed in 3 of 11 gill wet mounts. No other significant pathogens were detected.

Organosomatic data indicated that the natural smolts were in relatively good health. Condition factors and mesentery fat levels were similar to hatchery steelhead sampled at WCT (Table 6). The natural smolts were significantly smaller ($P < 0.01$) and had much lower Abnormality scores (better condition) than the hatchery emigrants.

Trinity R. Hatchery Steelhead (broodyear 90)

Skin infection by *Gyrodactylus* sp. was the only significant pathogen detected in the 1+ steelhead sampled at TRH 7 days prior to their volitional release (Table 7). Both the prevalence and intensity (number of worms/fish) of *Gyrodactylus* sp. infection was quite high, however, no associated lesions were observed in the fish. This external parasite was probably only a minor irritant to these fish. *Gyrodactylus* sp. was also observed on steelhead at WCT.

Three samples of TRH 1+ steelhead were taken at WCT ranging from 35 to 57 days post-release. The long period from hatchery release to capture at WCT could have been a result of the volitional nature of the release or a lack of migratory behavior. While raceway screens were removed on March 18th, a large percentage of this lot chose to stay in the hatchery for several weeks.

The emigrants captured at WCT showed a 10 % incidence of *Renibacterium salmoninarum* infection. Low numbers of bacteria in the positive samples indicate the infections were not severe.

While *R. salmoninarum* was not detected in pre-release samples from this lot, it is doubtful that the fish became infected after release from TRH. The 60 fish sample size is only reported to give the researcher a 95 % confidence level of detecting an infected individual if the disease is present in greater than or equal to 5 % of the population (Ossiander & Wedemeyer 1973). This detection level was reduced further by the limited sensitivity of the DFAT assay used in the study (Sakai et al. 1989).

WCT emigrants had a high incidence of glochidia infection (56 %) in their gills and metacercaria (presumptively *Nanophyetus salmincola*) were observed in a number of kidney samples. Neither parasite was observed in these fish at TRH.

TABLE 5. Natural Trinity River Steelhead Smolts: Prevalence of infection for virus in 4-fish pool kidney-spleen samples and Erythrocytic Inclusion Body Syndrome (EIBS) inclusions in individual blood smears, bacteria in 2-fish pool kidney-spleen samples, and parasites in individual imprints, smears, wet mounts and histological samples. Fish sampled on March 13, 1991 at the Willow creek trap. Reported as number positive over number sampled (% positive).

VIRUS	0/15 (0)
EIBS	0/56 (0)
BACTERIA	
<i>R. salmoninarum</i>	6/29 (21)
<i>A. hydrophila</i>	2/18 (11)
PARASITES	
Skin:	
<i>Ambiphrya</i> spp.	3/10 (30)
Gill:	
<i>Trichodina</i> spp.	1/10 (10)
Intestine:	0/10 (0)
Blood:	0/56 (0)
Kidney (Imprint):	0/30 (0)

TABLE 6. Comparison of Natural and Hatchery Steelhead smolt organosomatic analysis data. Twenty smolts of each group were examined at the Willow Creek Trap on March 13 (natural smolts) and April 22, 1991 (hatchery fish 35 d post release). Percentages reflect the number of fish in sample which meet the row criteria.

	NATURAL	HATCHERY
CUMULATIVE ABNORMALITY SCORE	0.75	2.10
ABNORMAL TISSUES ⁺		FINS ^{**} SKIN ⁺⁺
FAT LEVEL >0 (%)	30	35
SILVERED (%)	100	100

CONDITION FACTOR (k)		
mean	0.7339	0.7228
std	0.0408	0.0621
cv	5.56	8.59
LENGTH (mm)		
mean	181.50	208.65*
std	28.28	22.33
cv	15.58	10.70
WEIGHT (g)		
mean	47.23	67.94*
std	23.95	23.70
cv	50.71	34.88
HEMATOCRIT		
mean	45.50	53.45*
std	8.36	4.21
cv	18.37	7.88
PLASMA PROTEIN		
mean	5.30*	4.25
std	1.23	0.75
cv	23.20	17.64

* Significant at P < 0.01

** Left-ventral fin clip associated with lesions and rated abnormal.

+ Tissues listed if > 10 % of sample had abnormal rating in that tissue.

++ Scale loss > 30 % of body surface

std Standard deviation

cv **Coefficient of variation**

TABLE 7. Trinity Hatchery Steelhead Smolts: Prevalence and incidence of infection for virus in 4-fish pool kidney-spleen samples and Erythrocytic Inclusion Body Syndrome (EIBS) inclusions in individual blood smears, bacteria in 2-fish pool kidney-spleen samples, and parasites in individual imprints, smears, wet mounts and histological samples. Fish sampled on March 11 at Trinity R. Hatchery (TRH) 7 d prior to a volitional release and at the Willow creek trap (WCT) on April 22 (33 d post-release), May 6 (49 d post-release), and May 14, 1991 (57 d post-release) during emigration. Reported as number positive over number sampled (% positive).

	TRH	WILLOW CREEK TRAP				INCIDENCE
		22APR	06MAY	14MAY		
VIRUS	0/15 (0)	0/6	0/4	0/6	0/16 (0)	
EIBS	0/60 (0)	0/24	0/10	ND	0/34 (0)	
BACTERIA						
<i>R. salmoninarum</i>	0/30 (0)	0/12	1/8	2/11	3/31 (10)	
<i>A. hydrophila</i>	1/18 (6)	2/12	1/8	0/11	3/31 (10)	
PARASITES						
Skin:						
<i>Ambiphrya</i> spp.	8/10 (80)	0/12	ND	ND	0/12 (0)	
<i>Gyrodactylus</i> spp.	10/10 (100)	5/12	ND	ND	5/12 (42)	
Gill:						
<i>Trichophrya</i> spp.	5/5 (100)	2/10	0/9	0/17	2/36 (6)	
Glochidia	0/5 (0)	6/10	4/9	10/17	20/36 (56)	
Intestine:						
<i>Hexamita</i> spp.	0/10 (0)	0/5	1/16	ND	1/21 (5)	
Blood:	0/60 (0)	0/24	0/10	ND	0/34 (0)	
Kidney (Imprint):	0/30 (0)	0/23	ND	0/12	0/35 (0)	
Kidney (Histology):						
Metacercaria *	ND	ND	2/11	1/3	3/14 (21)	
* Metacercaria observed in kidney sections presumed to be <i>Nanophyetus salmincola</i>						
ND Not done.						

Histological sections showed only a mild inflammatory response to either of these parasites (Figs 2 & 3). The effect of these parasites on smolt health and saltwater adaptation is unclear from the limited data.

The hatchery steelhead sample at WCT showed a 60 % drop in the number of fish with visible mesentery fat, a 22 % decrease in mean condition factor, and an 11% increase in mean hematocrit in comparison to steelhead sampled 35 d early at TRH (Table 8). Differences in condition factor and hematocrit between the pre-liberation and WCT sample were significant at $P < 0.01$. Mean condition factor (K) at the hatchery (0.9280×10^5) was similar to the 0.9424×10^5 reported for steelhead (Piper et al 1982). Significantly larger fish ($P < 0.01$) were sampled at the WCT compared to those fish examined at TRH. Whether larger fish migrate at a faster rate (the organosomatic assays were performed on the first group of TRH steelhead to reach WCT) or the trap site was selective for larger fish is unclear.

A high incidence of hemorrhagic, open lesions were associated with the left-ventral fin clip given to this lot. The percentage of fish with > 30 % of their scales missing was much higher at WCT (100%) than at TRH (15%). While the 2- 3 days spent in the WCT livebox played a role in this scale loss, natural steelhead held for the same amount of time did not experience any scale loss. The effect of scale loss on the smolt's salinity tolerance is unclear, however, the empty scale pockets would likely increase skin permeability and provide portals for pathogens. Smith (1982) discussed a report of salmon mortality in saltwater due to scale-loss. If 30 % or more of the juvenile salmon's scales were removed, mortality occurred within 24 hours due to abnormally high plasma Mg^{++} . Scale loss and fin lesions contributed to high Abnormality scores given to these fish.

COHO

Natural Coho

Insufficient numbers of natural coho were captured at WCT during the course of the study to sample this group. Our criteria, of only sampling when a minimum of 20 fish/group were captured within 3 days, was not met as only 26 natural coho smolts were captured at WCT during the period of February 13 - November 22, 1992.

Trinity Hatchery Coho

This group was judged to be in poor health due primarily to Bacterial Kidney Disease.

There was a high prevalence (63 % in both TRH and WCT samples) and intensity of *Renibacterium salmoninarum* infection in these fish (Table). Clinical signs of severe BKD included low hematocrits, low plasma protein measurements, enlarged spleens (RBC retention), grey swollen kidneys, bacteria-laden monocytes found in bloodsmears, and *R. salmoninarum*-filled granulomas seen in gill sections from affected fish. The hematocrit and plasma protein values of coho sampled at TRH (mean HCT = 30.8, PL. Protein = 3.86) indicated some degree of anemia and hypoproteinemia in the population (Table). In comparison, samples taken from healthy Irongate hatchery coho smolts (Klamath R. stock) in 1991 had a mean hematocrit of 47 and plasma protein level of 5.6 g/dL (unpubl. data). Bacterial Kidney Disease will continue to progress in saltwater (Banner et al. 1983) and may result in high mortalities in this hatchery lot.

TABLE 8. Trinity Hatchery Steelhead Smolt organosomatic analysis data. Twenty fish were examined on March 11 at Trinity River Hatchery (TRH) 7 d prior to their volitional release and 35 d post-release at the Willow Creek Trap (WCT) on April 22, 1991. Percentages reflect the number of fish in sample which meet the row criteria.

	TRH	WCT
CUMULATIVE ABNORMALITY SCORE	1.60	2.10
ABNORMAL TISSUES ⁺	FINS** SKIN ⁺⁺	FINS** SKIN ⁺⁺
FAT LEVEL >0 (%)	95	35
SILVERED (%)	100	100
CONDITION FACTOR (k)		
mean	0.9280*	0.7173
std	0.0851	0.0709
cv	9.17	9.88
LENGTH (mm)		
mean	175.60	208.65*
std	11.39	22.33
cv	6.49	10.70
WEIGHT (g)		
mean	50.71	67.94*
std	9.78	23.70
cv	19.28	35.52
HEMATOCRIT		
mean	47.10	53.45*
std	3.35	4.21
cv	7.13	7.88
PLASMA PROTEIN		
mean	4.39	4.25
std	0.89	0.75
cv	20.35	17.64

* Significantly greater ($P < 0.01$).

+ Tissues listed if > 10 % of sample had abnormal rating in that tissue.

** Left-ventral fin clip associated with lesions and rated abnormal.

++ Thirty percent of sample with scale loss > 30 % of body surface.

std Standard deviation.

cv Coefficient of variation.

TABLE 9. Trinity Hatchery Coho Smolts: Prevalence and incidence of infection for virus in 4-fish pool kidney-spleen samples and Erythrocytic Inclusion Body Syndrome (EIBS) inclusions in individual blood smears, bacteria in 2-fish pool kidney-spleen samples, and parasites in individual imprints, smears, wet mounts and histological samples. Fish sampled on March 11 at the Trinity R. Hatchery (TRH) 7 d prior to a volitional release and at the Willow creek trap on May 14 (57 d post-release) and May 22, 1991 (65 d post-release) during emigration. Reported as number positive over number sampled (% positive).

	TRH	WILLOW CREEK TRAP		
		14MAY	22MAY	INCIDENCE
VIRUS	0/15 (0)	0/10	0/5	0/15 (0)
EIBS	13/47 (28)	0/40	0/18	0/58 (0)
BACTERIA				
<i>R. salmoninarum</i>	19/30 (63)	10/20	9/10	19/30 (63)
<i>A. hydrophila</i>	0/18 (0)	2/20	ND	2/20 (10)
PARASITES				
Skin:				
<i>Ambiphrya</i> spp.	0/10 (0)	1/10	ND	1/10 (10)
Gill:				
<i>Trichophrya</i> spp.	6/60 (60)	2/19	ND	2/19 (11)
Intestine:	0/10 (0)	0/8	0/4	0/12 (0)
Blood:	0/60 (0)	0/40	0/18	0/58 (0)
Kidney (Imprint):	0/30 (0)	0/20	0/20	0/40 (0)
Kidney (Histology):				
Metacercaria*	ND	2/9	ND	2/9 (22)
* Metacercaria observed in kidney sections presumed to be <i>Nanophyetus salmincola</i> .				
ND Not done.				

Erythrocytic inclusions, indicative of EIBS, were observed in 28 % of the TRH sample. Anemia is a major complication of EIBS infection (Piacentinia et al. 1989). While the mean TRH sample hematocrit of 30.8 is within normal range for salmonids (Wedemeyer and Yasutake 1977), 40 % of the fish sampled at the hatchery had hematocrits below this value and were considered slightly anemic. It is unclear why the coho sampled later at WCT had such elevated hematocrits (mean Hct = 59). An increase in erythrocytes may have been a compensatory response to the earlier anemia induced by EIBS and BKD. Other possible explanation for increased hematocrit include stress-related contraction of the spleen which would force additional erythrocytes into the circulation (Heath 1987), erythrocyte swelling due to exercise and anesthesia (Wells and Weber 1991), or erythrocyte swelling due to the buildup of CO₂ within the microhematocrit tube (Soivio and Nikinmaa 1981). Additional samples taken later at WCT to validate methodology also had high hematocrits (avg. = 50.4, SD = 9.2, n = 11). No erythrocytic inclusions were seen in blood smears collected from emigrant smolts at WCT. Whether fish recovered from the EIBS infection in the 57 - 65 d between the hatchery and WCT samples, or EIBS-infected fish did not migrate with the lead coho group, or EIBS affected smolts died prior to WCT is unclear.

Metacercaria, presumptively *Nanophyetus salmincola*, were observed in 22 % of kidney sections taken from WCT samples (Table 9). No significant inflammation was associated with the metacercaria cysts. Kidney samples (histological and wet mount) were not collected at TRH, however, no cysts were observed during necropsy. It is highly probable that the coho became infected with *Nanophyetus salmincola* while emigrating down the Trinity River. The only gill parasite observed at either TRH or WCT was *Trichophrya* sp.. The inability to detect glochidia in the coho may be related to this species' relative resistance to infection (Karna and Millemann 1978).

The high Abnormality scores at both TRH and WCT resulted from BKD lesions observed in various organs, fin erosion, and scale loss (Table 10). In comparison to coho sample 57 d earlier at TRH, there was a 90 % decrease in the number of fish with visible mesentery fat and a 32 % decrease in the mean condition factor of emigrants collected at WCT. Although body weights decreased, coho collected at WCT were similar in length to coho sampled at the hatchery. These data indicate that the rotary trap site was not selective for larger coho unlike the TRH chinook and steelhead groups.

TABLE 10. Trinity Hatchery Coho Smolt organosomatic analysis data. Twenty fish were examined on March 11 at Trinity River Hatchery (TRH) 7 d prior to their volitional release and 57 d post-release at the Willow Creek Trap (WCT) on May 14, 1991. Percentages reflect the number of fish in sample which meet the row criteria.

	TRH	WCT
CUMULATIVE ABNORMALITY SCORE	2.20	2.45
ABNORMAL TISSUES ⁺	FINS SPLEEN	FINS & SKIN KIDNEY
FAT LEVEL >0 (%)	100	10
SILVERED (%)	100	100

CONDITION FACTOR (k)		
mean	0.8205*	0.5619
std	0.0512	0.0344
cv	6.24	6.12
LENGTH (mm)		
mean	152.85	160.05
std	17.36	11.28
cv	11.35	7.05
WEIGHT (g)		
mean	31.18*	23.55
std	16.88	5.85
cv	54.14	24.83
HEMATOCRIT		
mean	30.80	58.95*
std	6.09	6.63
cv	19.77	11.25
PLASMA PROTEIN		
mean	3.86	4.30
std	1.08	1.02
cv	28.14	23.62

* Significantly greater (P < 0.01).

+ Tissues listed if > 10 % of sample had abnormal rating in that tissue.

std Standard deviation.

cv Coefficient of variation.

SUMMARY

Results from the 1991 survey indicate that *Renibacterium salmoninarum*, *Nanophyetus salmincola* metacercaria, and glochidia are common pathogens to Trinity river salmonids and may seriously impair the health of these fish. Bacterial kidney disease has long been a major limiting factor to salmonid hatchery success (Sanders and Fryer 1980). Similarly, a negative correlation between high levels of *N. salmincola* metacercarial infection and saltwater survival has been documented in coho and chinook (Lee Harrell, NMFS, Manchester Marine Lab, WA, pers. comm.). Heavy glochidia infections of the gill would act to reduce respiration capacity and upon excysting, result in hemorrhage and secondary infection (Karna and Millemann 1978). The inability to detect *Ceratomyxa shasta* in any group corresponds to the reported lack of *C. shasta* infectivity in the Trinity river (Hendrickson et al. 1989).

Nanophyetus salmincola metacercaria and glochidia may have a greater effect on hatchery fish than natural populations. Hatchery fish appear to face an acute challenge from these parasites following release from TRH, while natural fish would presumptively become infected over a longer period of time and may better tolerate the infections. Slower emigration, influenced by low river flow or non-migratory behavior, would expose TRH smolts to more cercaria (infective stage of *N. salmincola*) and glochidia. Increased exposure to these infective stages would result in higher intensities of parasite infection and disease. Parasite infection in these stocks could be reduced if TRH fish, in their final phases of smoltification, are released into river flows which rapidly move them into the Klamath estuary.

Viral disease in the hatchery may have affected emigration speed or survival in the TRH Spring chinook (IHNV) and coho (EIBS). The inability to detect these viral agents in emigrant spring chinook or coho sampled at WCT may be related to sample size, method sensitivity, or differential performance of infected compared to uninfected (recovered?) fish. Current diagnostic assays are not sensitive enough to consistently detect subclinical EIBS or IHNV infections in juvenile fish.

Future studies should utilize histology to better document parasite incidence and Enzyme Linked Immunosorbent Assay (ELISA) to detect low-level infections of *Renibacterium salmoninarum*. Coho salmon may be dropped from future studies due to the difficulty of capturing natural smolts. An examination of the physiological status of a selected study group may help correlate pathogen infection with smolt health.

Significant Results

- 1) *Renibacterium salmoninarum*, the agent of BKD, was detected in TRH steelhead, coho, and spring chinook, as well as natural steelhead. The TRH coho were judged to severely affected by BKD.
- 2) Metacercaria (presumptively *Nanophyetus salmincola*) were detected in TRH steelhead, coho, and spring chinook, as well as natural steelhead. Many fish had heavy infections and may have poor saltwater adaptation. It is unclear whether the natural chinook sampled were infected due to inappropriate methodology.
- 3) Glochidia were detected in TRH spring chinook and steelhead but not coho. This gill parasite was also seen in natural steelhead.
- 4) Viral infection in TRH spring chinook (IHNV) and coho (EIBS) sampled prior to release was not detected in WCT samples from these groups. It is unclear whether viral infection affected emigration.

5) The Willow creek rotary trap captured significantly larger TRH steelhead and spring chinook than were sampled prior to release at the hatchery. It is unclear whether trap location or a size-differential emigration timing caused this occurrence.

6) All TRH groups captured at WCT showed signs typical of smolt migration such as reduced mesentery fat, lower condition factors, increased hematocrits, and silver appearance. Scale loss, under comparable conditions, was more prevalent in hatchery fish than natural fish.

REFERENCES

- Banner, C.R., J.S. Rohovec, and J.L. Fryer. 1983. *Renibacterium salmoninarum* as a cause of mortality among chinook salmon in saltwater. *J. World Mariculture Soc.* 14:236-239.
- Bjornn, T.C. 1977. Wild fish production and management. American Fisheries Society Special Publication 10: 65-71.
- California Advisory Committee on Salmon and Steelhead Trout. 1988. Restoring the Balance, a report to the Legislature and the Department of Fish and Game. 84 pages. No. 124-J., Sausalito, CA.
- Craig, J. 1991. Annual report: Klamath river basin juvenile salmonid fisheries investigation 1989. Report No. AFF-1 FRO 91-3, U.S. Fish & Wildlife Service, Coastal California Fishery Resource office, Arcata, California. pp 81.
- Farrell, R.K., M.A. Lloyd and B. Earp. 1964. Persistence of *Neorickettsia helminthoeca* in an endoparasite of the Pacific salmon. *Science* 145:162-163.
- Foott, J.S. 1990. The organosomatic analysis system: A tool for evaluation of smolt quality. *In*: Proceedings of the Northeast Pacific chinook and coho salmon symposium, September 18-22, 1990, Arcata, California.
- Goede, R. W. and B. A. Barton. 1987. Organismic indices and autopsy-based assessments as indicators of health and condition in fish. Pages 93 - 108 *in* S. M. Adams editor, Biological Indicators of stress in fish. American Fisheries Society, Bethesda, Maryland.
- Heath, A.G. 1987. Water pollution and fish physiology. CRC Press, Boca Raton, Florida.
- Hedrick, R.P., S.E. LaPatra, J.L. Fryer, T. McDowell, and W.H. Wingfield. 1987. Susceptibility of coho (*Oncorhynchus kisutch*) salmon hybrids to experimental infections with Infectious Hematopoietic Necrosis Virus (IHNV). *Bull. Eur. Ass. Fish Pathol.* 7(4):97-100.
- Hendrickson, G. L., A. Carleton, and D. Manzer. 1989. Geographic and seasonal distribution of the infective stage of *Ceratomyxa shasta* (Myxozoa) in Northern California. *Diseases of Aquatic Organisms* 7: 165 - 169.
- Hoar, W.S. 1988. The physiology of smolting salmonids. Pgs. 275-343. *in*: W.S. Hoar and D.J. Randall eds., *Fish Physiology* Vol XI, Part B, Academic Press, New York.
- Hoffman, G. L. 1970. Parasites of North American freshwater fishes. University of California Press, Berkeley.
- Humason, G. 1979. Animal tissue techniques. 4th ed., W.H. Freeman and Co., San Francisco.
- Jennings, M.R. and G.L. Hendrickson. 1982. Parasites of chinook salmon (*Oncorhynchus tshawytscha*) and coho salmon (*O. kisutch*) from the Mad river and vicinity, Humboldt county, California. *Proc. Helminthol. Soc. Wash.* 49(2):279-284.
- Karna, D.W. and R.E. Millemann. 1978. Glochidiosis of salmonid fishes. III. Comparative susceptibility to natural infection with *Margaritifera margaritifera* (L.) (Pelecypoda: Margaritanidae) and associated histopathology. *J. Parasitol.* 64(3): 528 -537.

- LaPatra, S.E., K.A. Roberti, J.S. Rohovec, and J.L. Fryer. 1989. Fluorescent antibody test for the rapid diagnosis of infectious hematopoietic necrosis. *J. Aquatic An. Health.* 1:29-36.
- Leek, S. L. 1987. Viral erythrocytic inclusion body syndrome (EIBS) occurring in juvenile spring chinook salmon (*Oncorhynchus tshawytscha*) reared in fresh water. *Can. J. Fish. Aquatic Sci.* 37:148 - 154.
- Manzer, D. 1991. BKD - California experience. Abstract. Page 65. *in* S. Mangin ed., National workshop on bacterial kidney disease, Phoenix, Arizona, Nov. 19-21, 1991, U.S. Fish and Wildlife Ser., Arlington, VA.
- Meyers, T.R., R.E. Millemann, and C.A. Fustish. 1980. Glochidiosis of salmonid fishes. IV. Humoral and tissue responses of coho and chinook salmon to experimental infection with *Margaritifera margaritifera* (L.) (Pelecypoda: Margaritanidae). *J. Parasitol.* 66:274-281.
- Millemann, R.E. and S.E. Knapp. 1970. Biology of *Nanophyetus salmincola* and "salmon poisoning" disease. *Adv. Parasitol.* 8:1-41.
- Ossiander, F.J. and G. Wedemeyer. 1973. Computer program for sample sizes required to determined disease incidence in fish populations. *J. Fish. Res. Board Canada.* 30:1383-1384.
- Piacentini, S.C., J.R. Rohovec, and J.L. Fryer. 1989. Epizootiology of erythrocytic inclusion body syndrome. *J. Aquatic Animal Health* 1:173-179.
- Piper, R. G., I. B. McElwain, L. E. Orme, J. P. McCraren, L. G. Fowler, and J. R. Leonard. 1982. *Fish Hatchery Management*. U. S. Department of the Interior, Fish and Wildlife Service, Washington, D.C..
- Sakai, M., S. Atsuta, and M. Kobayashi. 1989. Comparison of methods used to detect *Renibacterium salmoninarum*, the causative agent of Bacterial Kidney Disease. *J. Aquat. An. Health.* 1(1):21-24.
- Sanders, J.E. and J.L. Fryer. 1980. *Renibacterium salmoninarum* gen. nov., sp. nov., the causative agent of bacterial kidney disease in salmonid fishes. *Int.J. of Systemic Bacteriol.* 30(2):496-502.
- Smith, L. S. 1982. *Introduction to Fish Physiology*. T.H.F. Publication Inc., new Jersey, pg 313.
- Soivio, A. and M. Nikinmaa. 1981. The swelling of erythrocytes in relation to the oxygen affinity of the blood of the rainbow trout, *Salmo gairdneri* Richardson. Pgs 103 -120, *In* A.D. Pickering editor, *Stress and fish*. Academic Press, New York.
- Wedemeyer, G.A. and W.T. Yasutake. 1977. Clinical methods for the assessment of the effects of environmental stress on fish health. *Fish & Wildlife Service, Tech. Paper* 89: 1-18.
- Wedemeyer, G. A., R. W. Gould, and W. T. Yasutake. 1983. Some potentials and limits of the leucocrit test as a fish health assessment method. *J. Fish Biol.* 23:711 - 716.
- Wells, R.M.G. and R.E. Weber. 1991. Is there an optimal haematocrit for rainbow trout, *Oncorhynchus mykiss* (Walbaum)? An interpretation of recent data based on blood viscosity measurements. *J. Fish Biol.* 38:53-65.
- Wood, E.M. and W.T. Yasutake. 1956. Histopathology of fish. II. The salmon-poisoning fluke. *Prog. Fish-Cult.* 18: 22-25.

Young, M. and J. Williams. 1984. The reproductive biology of the freshwater pearl mussel *Margaritifera margaritifera* Linn. in Scotland. II. Laboratory studies. Arch. Hydrobiol. 100:29-43.

APPENDICES

Appendix 1. Organosomatic analysis.

The organosomatic analysis system used in this study was modified from Goede's Fish Health and Condition Assessment System (Goede and Barton 1987). The system is an ordered observation and reporting of the gross morphology of selected organs, hematological measurements, and size criteria. A twenty fish sample collected in an unbiased manner from the population of interest is sufficient for the system (Goede and Barton 1987).

Goede's system was modified to better suit smolt evaluation needs and allow for comparison between temporal and geographically different populations of the same species and age. Leukocrit was removed from the nominal data group (length, weight, hematocrit, and plasma protein) which is analyzed by parametric statistics, and placed in with the subjective tissue and organ categories. Leukocrit is the packed volume of white blood cells and thrombocytes per unit volume of whole blood in a centrifuged microhematocrit sample (referred to as the buffy coat). Fish blood samples have relatively small buffy coats that require the use of a low power, ocular micrometer for accurate measurement (Wedemeyer et al. 1983). This microscopic procedure is tedious and time consuming. In Goede's system, leukocrit is roughly estimated with a hematocrit tube reader. Fin condition, skin condition, and degree of silver coloration (external sign of smoltification) were added to the examination list. Finally, the descriptive categories for each tissue or organ observation were numerically arranged to assess the severity of the observed abnormalities and summed to give each smolt a "abnormality" score. A low score reflects a fish in good condition.

In Goede's current system, a wide variety of abnormality codes are used to describe each organ or tissue. His report format lists all the observations which match each abnormality code as well as a summary of percent normal observations for each organ and tissue. This emphasis on observational percentages makes comparing multiple samples (populations) tedious. A mean "abnormality" score for the sample provides the user with a single value that could be quickly compared to other populations.

A separate weighed abnormality score is derived from weight factors multiplied by each organ's severity score. Each organ or measurement would be weighted by a factor of 0 (not included in scoring), 1 (minor), 2 (medium), and 3 (major) according to its perceived importance in saltwater adaptation and emigration. For example, kidney abnormalities would be weighed 3X more than fin condition (1X) since the kidney is critical in divalent ion excretion. The spreadsheet report allows for easy changes in weight factors. A description of the weight factors is listed below.

Organ/Measurement	Weight Factor	Importance
FIN	1X	
SKIN	2X	scale loss increases osmotic disfunction
EYE	2X	sight for food capture / predator avoidance
GILL	3X	chloride cell Na-K-ATPase needed for SW
PSEUDOBRANCH	1X	
THYMUS	1X	
SILVER INDEX	nd	silver color doesn't ensure SW adaptation
LIVER	2X	glycogen and lipid metabolism for energy
SPLEEN	2X	immune defenses

KIDNEY		3X	divalent ions excretion, blood formation
GASTRO-INTESTINE	2X		lower intestine involved in ion regulation
FAT = 0		nd	natural smolts rarely have mesenteric fat
HCT < 20 %	2X		abnormally low hematocrit (anemia)
PL.PR.< 2.0 g/dL	2X		abnormally low plasma protein (hypoproteinemia)

Examination steps

- 1) Fish are quickly captured, euthanized in an overdose of MS-222, and immediately bled from an incision in the caudal peduncle. Care is taken not to cut off the tail. Blood is collected in a heparinized microhematocrit tube, centrifuged at 10,000 rpm for 5 min., and measurements taken within 10 minutes. Once the packed erythrocyte volume (hematocrit) is determined with a tube reader and the leukocrit (packed volume of white blood cell or buffy coat which separate erythrocytes and plasma) is estimated with the tube reader, the tube is broken at the cell : plasma interface. Plasma is expressed into a serum refractometer chamber for protein concentration determination.
- 2) Fish are kept in order for all observations and measurements. While the blood samples are being centrifuged, the condition of the eyes, fins, skin (especially loss of scales), gills, pseudobranchs, thymus, and degree of silvering is determined for all the fish.
- 3) An incision is made from the branchial cavity to the anus with sharp / blunt scissors. Disruption of internal organs is avoided. The condition of the liver, spleen, kidney, gastro-intestinal tract, and the amount of mesenteric fat is recorded for each fish.
- 4) Total length (mm) and body weight (g) are recorded for each fish. Condition factor ($wt \times 10^5 / Length^3$) is calculated for each fish.
- 5) Samples for microbiological assays are then taken.

SMOLT ORGANOSOMATIC ANALYSIS

Twenty fish / lot

Continuous nominal data: Mean, Standard deviation, and coefficient of variation calculated.

LENGTH TOTAL LENGTH (SNOUT - TIP OF TAIL) millimeters

WEIGHT grams

CONDITION FACTOR (K) $\frac{W \times 10^5}{L^3}$

HEMATOCRIT VOL. RBC PACK / BLOOD SAMPLE VOL x 100
(x2 IF < 20 %) 5 MIN. CENTRIFUGE @ 10,000 RPM

PLASMA PROTEIN g/dL total protein (triple scale refractometer)
(x2 IF < 2.0 g/dL)

Subjective ordinal data (X weight factors)

FINS x1 0 - NO ABNORMALITY, WELL SHAPED
(SOME OR ALL) 1 - DISCOLORED/CLUBBED/FRAYED, < 30 % EROSION
2 - > 30 % EROSION BUT STILL VISIBLE
3 - ERODED TO THE BASE OR HEMORRHAGING

<u>SKIN</u> x2	<ul style="list-style-type: none"> 0 - NORMAL COLORATION AND SCALE NUMBERS 1 - DARKEN/HIGH MUCUS AMT., < 30 % SCALE LOSS 2 - ABRASION, FUNGAL INFECTION, > 30% SCALE LOSS 3 - OPEN LESIONS
<u>EYES</u> x3	<ul style="list-style-type: none"> 0 - NO ABNORMALITIES 1 - CATARACTS, PARASITES, MISSING ONE EYE, DIMINUTIVE 2 - EXOPHTHALMOS 3 - HEMORRHAGES
<u>GILLS</u> x3	<ul style="list-style-type: none"> 0 - NORMAL COLORATION AND LAMELLAR STRUCTURE 1 - PALE (ANEMIA) 2 - CLUBBED (SLIGHT HYPERPLASIA), FRAYED AT TIP, NODULES 3 - FUSED LAMELLAE, HEMORRHAGING, NECROTIC
<u>PSEUDOBRANCHS</u> x1	<ul style="list-style-type: none"> 0 - NORMAL COLORATION AND STRUCTURE 1 - SWOLLEN AND/OR LITHIC 2 - HEMORRHAGES 3 - NECROTIC
<u>THYMUS</u> x1	<ul style="list-style-type: none"> 0 - NORMAL COLORATION AND STRUCTURE 1 - FEW PETECHIAL HEMORRHAGES 2 - MODERATE HEMORRHAGING 3 - NECROTIC
<u>SILVERING</u>	<ul style="list-style-type: none"> 0 - FULLY SILVER, NO PARR MARKS 1 - SILVER WITH FAINT PARR MARKS 2 - HINT OF SILVER WITH DISTINCT PARR MARKS 3 - NO SILVERING
<u>LEUKOCRIT</u> x0	<ul style="list-style-type: none"> 0 - NOT VISIBLE OR < 2.0 UNIT ON TUBE READER 1 - > 2.0 UNITS ON TUBE READER (LEUKOCYTOSIS)
<u>LIVER</u> x2	<ul style="list-style-type: none"> 0 - NORMAL SIZE, RED OR LIGHT RED 1 - PALE OR YELLOW COLORATION AND/OR "FATTY" TO TOUCH 2 - NEMATODES, FOCAL DISCOLORATION 3 - LESIONS (NODULES, HEMORRHAGING)
<u>SPLEEN</u> x2	<ul style="list-style-type: none"> 0 - NORMAL SIZE, RED OR DARK RED IN COLOR 1 - ENLARGED 2 - FOCAL DISCOLORATION, LESIONS PRESENT 3 - "LIQUIFIED" STATE, SEVERE HEMORRHAGING
<u>KIDNEY</u> x3	<ul style="list-style-type: none"> 0 - NORMAL SIZE , VENATION APPARENT 1 - NEPHROCALCINOSIS, PALE (ANEMIA) 2 - SWOLLEN, NORMAL RED COLORATION 3 - NODULES, GREY SWOLLEN APPEARANCE, OR "LIQUIFIED"
<u>GI TRACT</u> x2	<ul style="list-style-type: none"> 0 - NORMAL COLORATION & MORPHOLOGY (FOOD +/-) 1 - YELLOW CATARRHAL EXUDATE 2 - MILD HEMORRHAGING

3 - SWOLLEN & HEMORRHAGIC, STOMACH FLUID FILLED

MESENTERY FAT (x 0)

0 - NONE IN PERITONEAL CAVITY (CAV) OR ON PYLORIC CECA (PC)

1 - CAV FAT < DIA. OF PC AND/OR < 50% COVERAGE OF PC

2 - CAV FAT = DIA. OF PC AND/OR > 50% COVERAGE OF PC

3 - CAV SOLID WITH FAT AND/OR PC OBSCURED BY FAT

Appendix 2. Organosomatic analysis reports. (This appendix not included in KRIS bibliography).